

## Case Report

# Malignant Solitary Fibrous Tumor of the Pleura

Siyami AYDIN<sup>1</sup>, Muharrem ÇAKMAK<sup>1,a</sup>, Sema AK<sup>1</sup>, İlknur ÇALIK<sup>2</sup>

<sup>1</sup>Fırat Üniversitesi Tıp Fakültesi, Göğüs Cerrahisi Anabilim Dalı, Elazığ, Türkiye

<sup>2</sup>Fırat Üniversitesi Tıp Fakültesi, Patoloji Anabilim Dalı, Elazığ, Türkiye

### ABSTRACT

The malignant solitary fibrous tumor of the pleura is a spindle cell mesenchymal tumor originating from fibroblasts. It is a very rare tumor. It develops from mesenchymal cells of the submesothelial tissue of the visceral pleura. Malignant solitary fibrous tumors originating from the parietal pleura are even more rare. In this study, we aimed to share a patient with malignant mesenchymal fibrous tumor originating from the parietal pleura and invading the rib.

**Keywords:** Parietal Pleura, Solitary Fibrous Tumor, Surgery.

### ÖZ

#### Plevranın Malign Soliter Fibröz Tümörü

Plevranın malign soliter fibröz tümörü fibroblastlardan köken alan, iğsi hücreli mezenkimal bir tümördür. Oldukça nadir görülen bir tümördür. Visceral plevranın submezotelyal dokusunun mezenkimal hücrelerinden gelişir. Pariyetal plevradan köken alan malign soliter fibröz tümörler çok daha nadirdir. Çalışmamızda, intratorasik yerleşimli, pariyetal plevradan köken alan, kaburga invazyon yapan ve malign soliter fibröz tümör tanısı alan olguyu paylaşmayı amaçladık.

**Anahtar Sözcükler:** Pariyetal Plevra, Soliter Fibröz Tümör, Cerrahi.

**Bu makale atıfta nasıl kullanılır:** Aydın S, Çakmak M, Ak S, Çalık İ. Plevranın Malign Soliter Fibröz Tümörü. Fırat Tıp Dergisi 2022; 27(3): 231-234.

**How to cite this article:** Aydın S, Çakmak M, Ak S, Çalık İ. Malignant Solitary Fibrous Tumor of the Pleura. Fırat Med J 2022; 27(3): 231-234.

**ORCID IDs:** S.A. 0000-0002-6889-8887, M.Ç. 0000-0002-9504-2689, S.A. 0000-0001-8668-7277, İ.Ç. 0000-0003-2160-7453

**S**olitary fibrous tumor (SFT) of the pleura is rare. It is a spindle cell mesenchymal tumor originating from fibroblasts. They often develop from mesenchymal cells of the submesothelial tissue of the visceral pleura. Malignant solitary fibrous tumors (MSFT) originating from the parietal pleura are even more rare. They are equally common in both sexes and are most commonly seen between the ages of 50-80 and they are usually asymptomatic (1).

In large lesions, cough, chest pain, dyspnea may occur. In some patients, clubbing, hypertrophic pulmonary osteoarthropathy (HPO), refractory hypoglycemia may be seen as paraneoplastic lesions. Radiologically, they appear as rounded masses associated with pleura, with smooth borders. Eighty percent of these tumors originate from the visceral pleura and can reach the dimensions to fill the hemithorax (2).

Although known as slow-growing lesions and histopathologically considered benign, they can rapidly reach large sizes. According to current literature 12% of the cases may show malignant behavior. Infiltration into the surrounding tissue is a sign of malignancy. In the treatment, total removal of the mass is recommended. Resection provides complete treatment in 90% of patients. Long-term follow-up is recommended in the

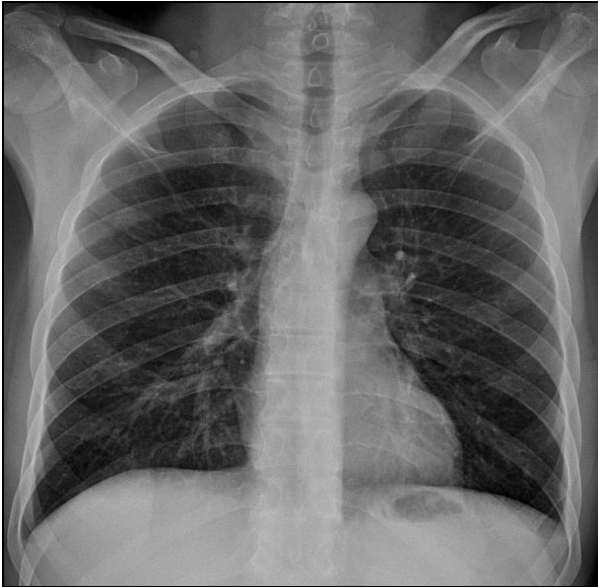
postoperative period. The place of chemotherapy and radiotherapy should be discussed (3, 4).

In this study, we aimed to share a patient with MSFT very rare seen and originating from the parietal pleura.

### CASE REPORT

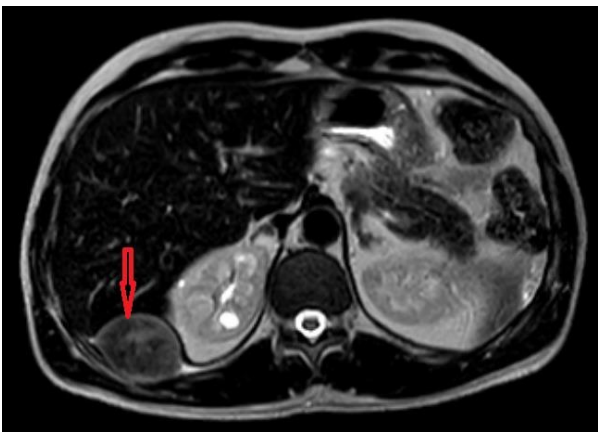A 44-year-old male patient was admitted to our clinic with severe pain in the right inferolateral hemithorax. Routine laboratory tests (hemogram, biochemistry and urine results) were normal.

There wasn't any feature in the patient's history. There was no history of trauma. There was no obvious pathology in the chest radiography of the patient (Figure 1).



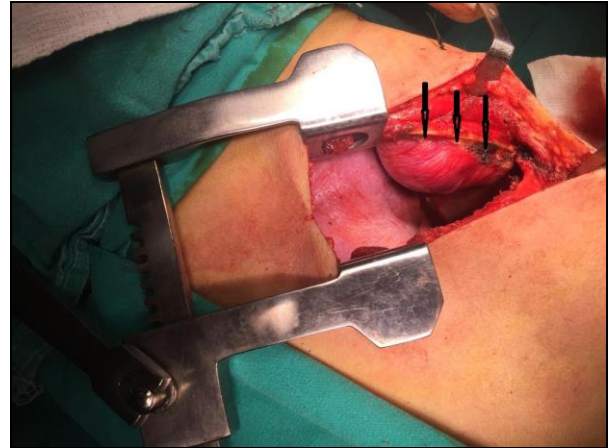
**Figure 1.** Chest X-ray of the patient.

Thoracic magnetic resonance imaging (MRI) was requested to evaluate both intrathoracic and intraabdominal regions (liver and kidney pathology?). MRI revealed 5x3.5cm mass lesion in right 8th rib inferior. It was observed that the mass was pressing on the diaphragm. The mass was heterogeneous hyperintense with respect to muscle in T2A, isointense with muscle in T1A and was showing heterogeneous enhancement (Figure 2).



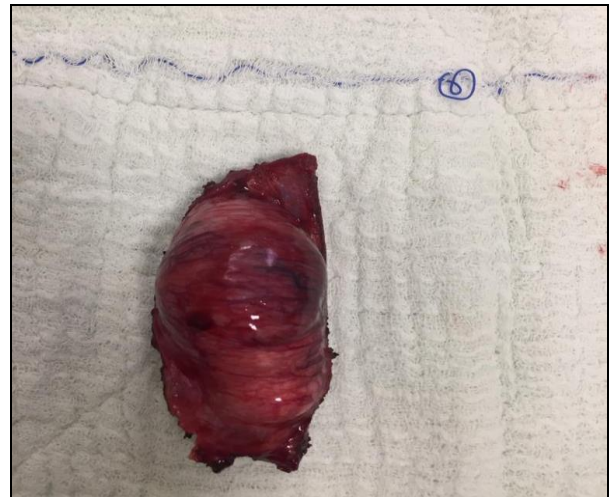**Figure 2.** Magnetic resonance image of the patient (axial).

Transthoracic biopsy was performed under the guidance of radiology. Although the biopsy result was considered as 'SFT' primarily, excision of the lesion was recommended for definitive diagnosis and typing considering the heterogeneity of soft tissue tumors. The operation was planned. During the operation, it was seen that the mass originated from the parietal pleura and invaded the 8th rib. The mass was excised to include intact bone and pleural tissue (Figure 3a).



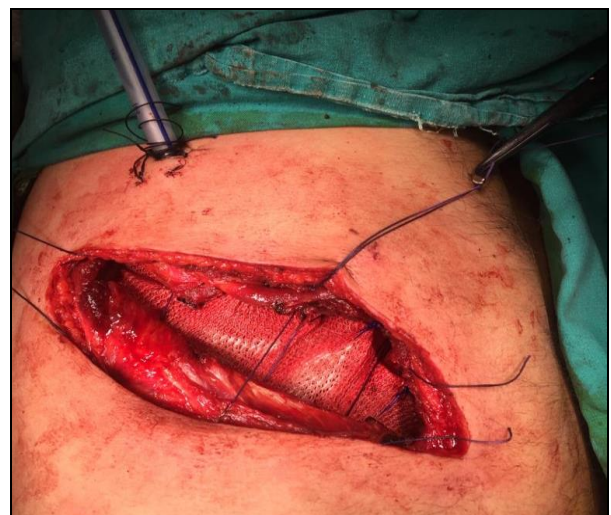**Figure 3a.** Intraoperative image of the mass 1.

An approximately 7-8 cm rib resection was performed (Figure 3b).



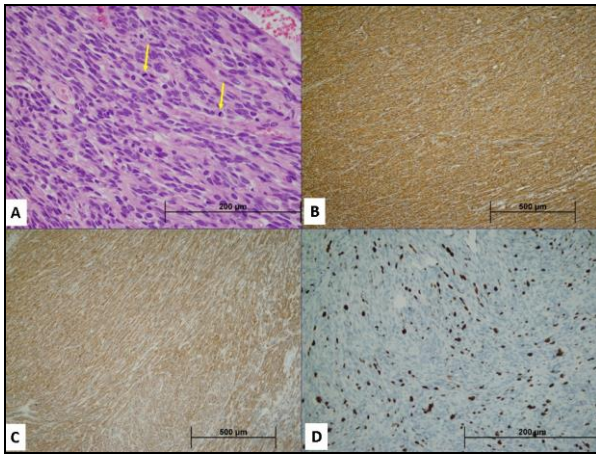
**Figure 3b.** Intraoperative image of the mass 2.

The 7-8x4-5cm chest wall defect that occurred after resection was reconstructed using mesh and surrounding intact tissue (Figure 4).



**Figure 4.** Reconstruction of surgical area.

The pathology result was reported as MSFT. Surgical margins were negative (Figure 5).



**Figure 5.** Haematoxylin and eosin staining (original magnification  $\times 200$ ) showing mitotically active (arrows) atypical spindle shaped cells arranged in interlacing fascicles (A). Immunohistochemical staining of tumor cells were positive for CD34 (B) and Bcl-2 (C). Ki-67 (MIB-1) proliferation index was 15-20% (D).

Oncology consultation was requested after pathological diagnosis. The patient was followed-up by us for about 6 months. There was no surgical problem observed, in terms of tumor and the patient was followed up by oncology.

## DISCUSSION

SFT are masses that originate from visceral pleura and connect to the pleura with a thin stem. They are seen equally in both sexes and most commonly between the ages of 50-80 (2). Our patient was a 44-year-old male patient.

Solitary fibrous tumors constitute 5% of tumors in the pleura and develop from mesenchymal connective tissue. These tumors are usually located in the outer region of the lung or interlobar fissure (5). In our patient, the tumor originated from the parietal pleura and was located in the chest wall.

They are round or oval in a single mass. The mass can be small or very large. They are usually asymptomatic and occur incidentally in the thorax x-ray. Symptoms are caused by compression of the lung or a large airway with a growing tumor. Cough, chest pain and shortness of breath are the most common complaints (6). HPO is seen in 20% of patients and hypoglycemia is seen in 3-4%. Hypoglycemia occurs due to secretion of an insulin-like peptide by the tumor or excessive glucose consumption by the mass. HPO and hypoglycemia are seen in tumors larger than 7 cm (7). In our patient, routine laboratory tests (hemogram, biochemistry and urine results) were normal.

Diagnosis is made by radiological and histological examination. Tumors originating from the visceral pleura are connected to the lung with a pedicle. These tumors show a mobile image with respiration during fluoroscopic examination and this is pathognomonic. Pleural effusion is also present in 8% of the cases. MRI shows low-moderate heterogeneous signal intensity on T1-T2 sections. The role of positron emission tomography in the evaluation of these tumors is unknown (3). The definitive diagnosis is made by histological examination. Bcl-2, CD-99, CD34 and vimentin were positive in the SFT (6). Tumor cells in our patient were positively stained with CD34, Bcl-2 and CD99. The Ki-67 (MIB-1) proliferation index was 15-12%.

The definitive treatment of these tumors is achieved by complete removal of the mass. Recurrence is rare (2%). If the tumor is attached to the visceral pleura, it should be removed enblock with lung tissue. In order to obtain an adequate surgical margin, it should be removed from the normal 2 cm tissue around the tumor. Extrapleural dissection can be performed in cases adherent to the thoracic wall. Chest wall resection should be performed in cases where there is no correct surgical plan. While recurrence is more common in malignant tumors, long-term survival is much better in benign tumors. The recurrence rate in benign tumors is 8%. In malignant tumors, if the tumor has a particularly flat appearance and originates from the parietal pleura, recurrence occurs in two-thirds of patients despite complete surgical resection and the mean survival after recurrence is 2 years (5). Our patient was excised to cover the intact bone tissue and pleura. Chest wall defect was reconstructed using mesh and surrounding intact tissues.

In conclusion, SFT are not common tumors. Parietal pleura involvement is very rare. SFT should not be ignored in the differential diagnosis of the patients with malignant masses in the chest wall. It can be successfully treated with surgical interventions. Therefore, it should be considered in the differential diagnosis of solitary lesions in the parietal pleura.

### Declaration of patient consent

The authors certify that they have obtained all appropriate patient consent forms. In the form the patient(s) has/have given his/her/their consent for his/her/their images and other clinical information to be reported in the journal. The patients understand that their names and initials will not be published and due efforts will be made to conceal their identity, but anonymity cannot be guaranteed.

### Financial support and sponsorship

The authors received no financial support for the research and/or authorship of this article.

### Conflicts of interest

There are no conflicts of interest.

**REFERENCES**

1. Berktaş B. Mesenchymal tumors of the pleura. Erdogan Y, Capan N, Demirag F, ed. Rare tumors of the thorax. Atatürk Chest Diseases and Chest Surgery Education and Research Hospital 2010: 307-11.
2. Robinson LA. Solitary fibrous tumor of the pleura. Cancer Control 2006; 13: 264-9.
3. Shields TW, Yeldani AV. Localized fibrous tumors of the pleura In: Shields TW, General Thoracic Surgery, seventh ed, vol 1, Lippincott Williams & Wilkins. Philadelphia 2009; 835-845.
4. Gou J, Chu X, Sun Y et al. Giant solitary fibrous tumor of the pleura: an analysis of five patients. World J Surg 2010; 34: 715-20.
5. De Perrot M, Fischer S, Brundler MA, Sekine Y, Keshavjee S. Solitary fibrous tumors of the pleura. Ann Thorac Surg 2002; 74: 285-93.
6. Liu CC, Wang HW, Li FY, Hsu PK, Huang MH, Hsu WH et al. Solitary fibrous tumors of the pleura: clinicopathological characteristics, immunohistochemical profiles, and surgical outcomes with long-term follow-up. Thorac Cardiovasc Surg 2008; 56: 291-7.
7. Bini A, Brandolini J, Davoli F, Dolci G, Sellitri F, Stella F. Solitary fibrous tumor of the pleura: Surgery and clinical course in 18 cases. Asian Cardiovasc Thorac Ann 2009; 17: 378-81.