

Olgu Sunumu

Traumatic Diafragmatic Rupture with Transthoracic Organs Herniation: A Rare Case Report

Yusuf DOĞAN^{1,a}, Mustafa KOÇ¹

¹Firat University Faculty of Medicine, Department of Radiology, Elazığ, Turkey

ABSTRACT

Traumatic diaphragmatic rupture (TDR) is a serious condition seen with 3% - 8% estimated incidence at blunt abdominal traumatic events. A missed diagnosis may occur on computed tomography (CT) at a range of about 10% - 60%. There are a lot of diagnostic pitfalls like anatomical and congenital variants and acquired abnormalities in this condition. The patient with TDR that missed diagnosis can present with transthoracic organ herniation or strangulation. These complications have a mortality rate of 30% - 60%. The diagnosis of TDR on imaging is essential for early surgical repair of diaphragm injury. A 35-year-old man was brought to the emergency department by ambulance because of falling from high. The patient had multiple blunt traumas and a full body CT was obtained. The left hemi-diaphragmatic defect with intrathoracic herniation of the stomach and colon was seen on CT. Thereupon the patient was taken to the operation room urgently. The diaphragmatic hernia was repaired. No additional complications were observed in the patient. Our aim in this report is to raise awareness of these serious cases of blunt abdominal traumatic events.

Anahtar Sözcükler: Traumatic Diaphragmatic Rupture, Transthoracic Herniation, Computed Tomography.

ÖZ

Transtorasik Organ Herniasyonunun Eşlik Ettiği Travmatik Diyafragma Rüptürü: Nadir Olgu Sunumu

Travmatik diyafram rüptürü (TDR), künt abdominal travmatik olaylarda tahmini insidansı %3-8 olan ciddi bir durumdur. Bilgisayarlı tomografi ile atlanmış tanı oranı %10-60 aralığında olabilmektedir. Anatomik ve konjenital varyasyonlar, sonradan edinilmiş anormallikler gibi birçok tanısal tuzak mevcuttur. TDR tanısı atlanmış hastalar transtorasik organ herniasyonu veya strangülasyon ile başvurabilmektedir. Bu komplikasyonların mortalite oranı %30-60'dır. Diyafram yaralanmasının erken cerrahi onarımı için görüntüleme TDR tanısı esastır. 35 yaşındaki erkek hasta yüksekten düşme nedeniyle ambulansla acil servisimize getirildi. Çoklu künt travmaları mevcut olan hastaya tüm vücut bilgisayarlı tomografisi (BT) çekildi. BT'de mide ve kolonun intratorasik herniasyonu ile birlikte sol hemidiyafragma defekti görüldü. Bu durum üzerine hasta acilen operasyona alındı. Diyafragma hernisi onarıldı. Operasyon sonrası hastada ek komplikasyon izlenmedi. Bu sunumdaki amacımız, ciddi künt abdominal travmatik vakalarda farkındalığı artırmaktır.

Keywords: Travmatik Diyafram Rüptürü, Transtorasik Herniasyon, Bilgisayarlı Tomografi.

Bu makale atıfta nasıl kullanılır: Doğan Y, Koç M. Transtorasik Organ Herniasyonunun Eşlik Ettiği Travmatik Diyafragma Rüptürü: Nadir Olgu Sunumu. Firat Tıp Dergisi 2023; 28(3): 241-244.

How to cite this article: Dogan Y, Koc M. Traumatic Diafragmatic Rupture with Transthoracic Organs Herniation: A Rare Case Report. Firat Med J 2023; 28(3): 241-244.

ORCID IDs: Y.D. 0000-0002-4098-3123, M.K. 0000-0002-3028-6068.

Traumatic diaphragmatic rupture (TDR) is a rare condition in all trauma events but also it could occur in 3% - 8% of blunt abdominal or lower thoracic traumatic events (1, 2). Diaphragm ruptures were reported in less than 0.5% of all traumas and missed diagnosis rate is about 10% - 60% on computed tomography (CT) (2, 3). Delayed or missed diagnosis in TDR can cause life-threatening results. TDR can stay silent clinically. Catastrophic complications are problem for these patients (4). CT is the best modality of TDR diagnosis. Furthermore, CT helps to show accompanying other abdominal, bone, and thoracic injuries in these patients (5). In this case report, we aim to raise radiology's awareness of these serious cases in the blunt abdominal

or lower thoracic traumatic events.

CASE REPORT

A 35-year-old man was admitted to our hospital emergency department by ambulance. We were informed that he had multiple blunt traumas because of falling from high. A full body CT scan was performed emergently to diagnose all injuries. Thorax and abdominal CT showed discontinuity of the left hemi-diaphragm with intrathoracic herniation of the stomach and colon (Figure 1a-c).

^aYazışma Adresi: Yusuf DOĞAN, Firat University Faculty of Medicine, Department of Radiology, Elazığ, Turkey

Tel: 0553 202 5815

Geliş Tarihi/Received: 14.02.2022

e-mail: yusufdogan9321@gmail.com

Kabul Tarihi/Accepted: 13.12.2022

* This study was presented as a oral at Turkish Magnetic Resonance Association 25th annual scientific meeting with international participation (16-18 Nisan 2020, Ankara).

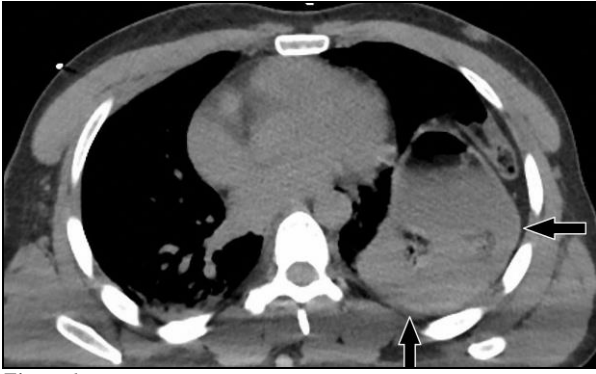


Figure 1a

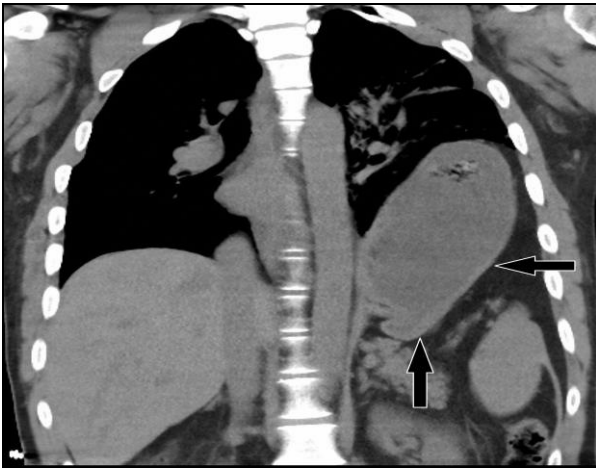


Figure 1b

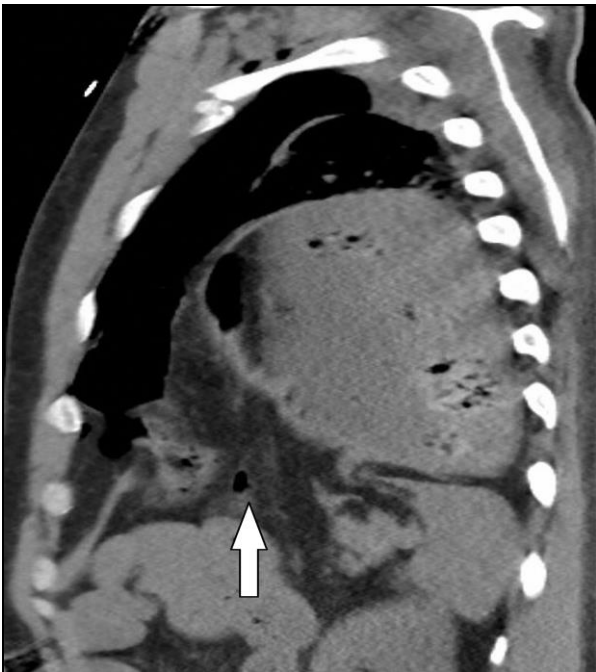

Figure 1c

Figure 1 a-c: Thorax and abdominal CT showed that discontinuity of the left hemi diaphragm with intrathoracic herniation of the stomach and colon Axial (a), Coronal (b), Sagittal (c), (arrows).

The diaphragmatic defect length was approximately 10 centimeters. The patient had several other traumatic injuries, including multiple rib fractures, left pneumo-

thorax, bilateral pulmonary contusion, grade 2 splenic lacerations, left retroperitoneal hemorrhage, right adrenal hemorrhage, intramural bowel hemorrhage, brain hemorrhage (subarachnoid hemorrhage), maxillofacial bone fractures, left lower and upper extremity fractures and lumbar transverse process fractures (Figure 2a-c).

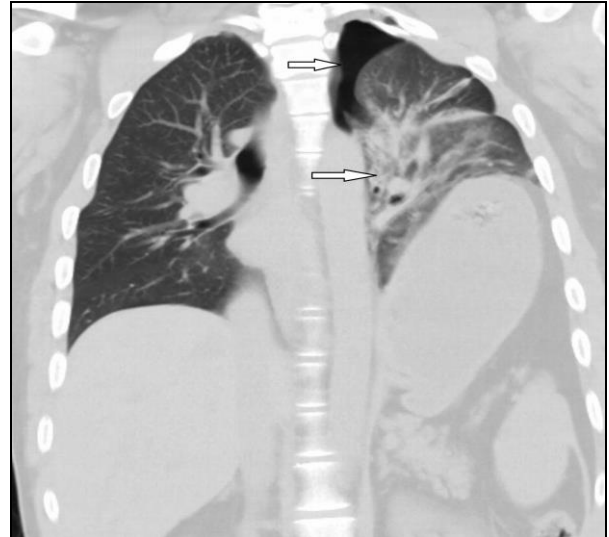

Figure 2a

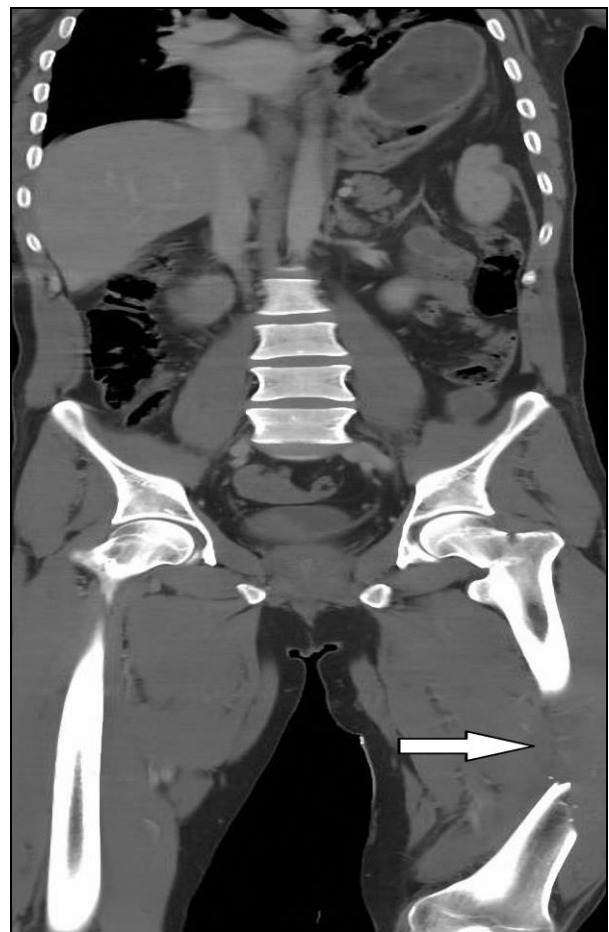


Figure 2b

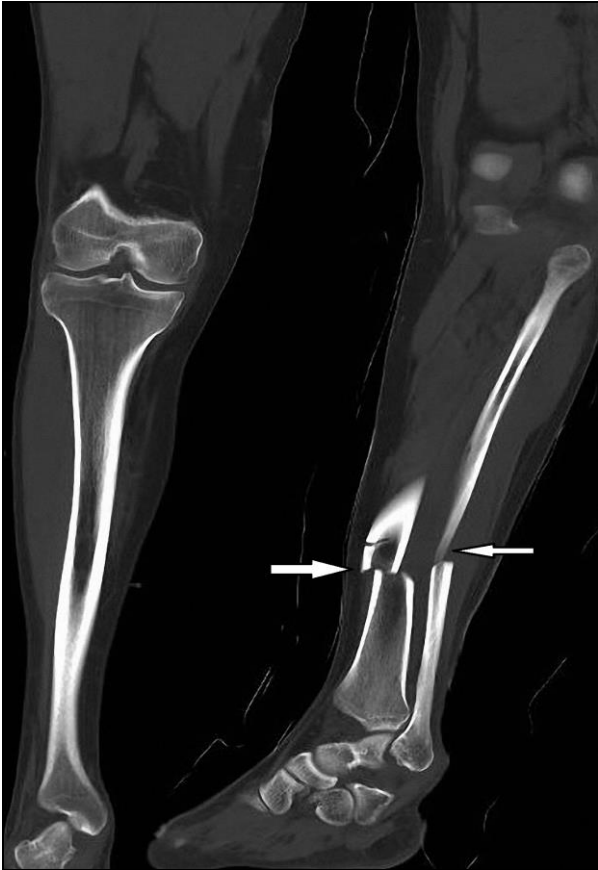

Figure 2c

Figure 2 a-c: The patient had several other traumatic injuries, including left pneumothorax and pulmonary contusion (a), decomposed fracture of the left femur (b), and fracture of the left tibia and fibula bone (c), (arrows).

The patient was taken emergently to the operating room and underwent an exploratory laparotomy. Trans-thoracic herniated organs were observed and these organs were reduced to the abdomen. The diaphragmatic defect was repaired surgically. The treatment was continued for other pathologies as well.

DISCUSSION

TDR is frequently seen in young men and it occurs with blunt or penetrating traumas. It is most frequently observed in motorcycle accidents. The pathophysiology of this injury is speculative. The most accepted hypothesis describes an increased intra-abdominal pressure following a blunt mechanism creating a sufficiently high-pressure gradient with the chest and abdomen to cause rupture and subsequent visceral intra-thoracic herniation. Right side of diaphragm is supported by liver, because of this the most common side of the injury is left. Left side injury occurs %68 of all diaphragm injuries. The most common injury location is the posterolateral side of the hemi-diaphragm.

There are many imaging techniques such as chest radiography, fluoroscopy, ultrasonography, CT, and magnetic resonance imaging (MRI) to use for diagnosis. Chest radiography is the first imaging modality in these conditions. Chest radiography helps to diagnose only 20-34% of patients with TDR. CT is the most useful imaging technique to evaluate TDR. CT also provides examination of other abdominal organs, lungs, and bones. The discontinuation of the diaphragm and diaphragmatic thickening are the most common findings on CT. For the left sided diaphragmatic ruptures, CT examination sensitivity-specificity was 78% and 100% respectively. For the right sided diaphragmatic ruptures, CT examination sensitivity-specificity was 50% and 83% respectively (2, 6).

Diaphragmatic injuries are very important to diagnose. There must be a high energy force to cause the rupture of diaphragm. At the same time, there can be other life-threatening injuries with diaphragmatic rupture (7). Chest and pelvis radiographs are often obtained firstly in patients with blunt multi-trauma. The presence of pneumothorax and rib fractures on chest radiography increases the possibility of abdominal injury. Pneumothorax, hemothorax, pneumoperitoneum are other common findings seen in patients with blunt multi-trauma on chest radiography. Ultrasonography plays an important role in the initial evaluation of blunt abdominal trauma. The presence of free fluid in the abdomen is investigated by focused evaluation with sonography (FAST) in trauma. Hemoperitoneum due to solid organ injury can be detected by ultrasonography. Computed tomography is the most sensitive imaging modality for patients with stable multi-trauma with suspected intraabdominal injury. Computed tomography provides valuable information in terms of injury severity and prognosis in intra-abdominal injuries. However, many studies have shown that computed tomography is less sensitive in detecting diaphragmatic and intestinal injuries (8). Chest and splenic injuries are the most common injury that occur with diaphragmatic rupture. Missed diagnosis in these cases have a potential morbidity rate of 30 % and mortality rate as high as 10% at diaphragmatic rupture. If missed diagnosis present with transthoracic herniation later, mortality rate rises to 30%-60%. Treatment principles of diaphragmatic rupture are repairing the defect by forming watertight closure, reducing herniated organs to abdomen and placing chest tube in the hemi thorax (9). In conclusion, TDR is an important condition that could be overlooked in the acute phase of cases. Serious complications like transthoracic organ herniation, and strangulation could occur in critical cases. CT is the best imaging modality to show TDR with these complications.

REFERENCES

1. Fair KA, Gordon NT, Barbosa RR et al. Traumatic diaphragmatic injury in the American College of Surgeons National Trauma Data Bank: A new examination of a rare diagnosis. *Am J Surg* 2015; 209:864-8.
2. Nchimi A, Szapiro D, Ghaye B et al. Helical CT of blunt diaphragmatic rupture. *AJR Am J Roentgenol* 2005; 184: 24-30.
3. Mahamid A, Peleg K, Givon A et al. Blunt traumatic diaphragmatic injury: A diagnostic enigma with potential surgical pitfalls. *Am J Emerg Med* 2017; 35: 214-7.
4. Mahmoud AF, Raeia MME, Elmakarem MAA. Rupture diaphragm: Early diagnosis and management. *J Egypt Soc Cardio-Thor Surg* 2017; 25: 163-70.
5. Murray JG, Caoili E, Gruden JF, Evans SJ, Halvorsen RA, Mackersie RC. Acute rupture of the diaphragm due to blunt trauma: diagnostic sensitivity and specificity of CT. *AJR Am J Roentgenol* 1996; 166: 1035-9.
6. Nursal TZ, Ugurlu M, Kologlu M, Hamaloglu E. Traumatic diaphragmatic hernias: a report of 26 cases. *Hernia* 2001; 5: 25-9.
7. Iadicola D, Branca M, Lupo M et al. Double traumatic diaphragmatic injury: A case report. *Int J Surg Case Rep* 2019; 61: 82-5.
8. Mama N, Jemni H, Achour NA et al. Abdominal trauma imaging. In *Abdominal Surgery Intech Open* 2012.
9. Furak J, Athanassiadi K. Diaphragm and transdiaphragmatic injuries. *J Thorac Dis* 2019; 11: 152-7.