

Case Report

Tracheobronchomegaly (Mounier-Kuhn Syndrome)

Ayşe MURAT AYDIN^{a1}, Ahmet Kursad POYRAZ¹, Hakan ARTAS¹, Teyfik TURGUT²

¹Firat University Faculty of Medicine, Department of Radiology, Elazığ, Turkey

²Firat University Faculty of Medicine, Department of Chest Diseases, Elazığ, Turkey

ABSTRACT

Tracheobronchomegaly (Mounier-Kuhn syndrome) is defined as marked cystic tracheobronchial dilatation. Tracheobronchomegaly (TBM) is a rare condition primarily affecting men between the ages of 40 to 50 years. The etiology of TBM is unknown. Pathologically, there is atrophy of the muscular and elastic elements of the trachea and central bronchi. The diagnosis of TBM and the associated pathology of the respiratory system are primarily based on radiographic examinations such as plain chest radiographs and CT scans. We report two cases of TBM with a history of recurrent lower respiratory tract infections.

Key words: Tracheobronchomegaly, Mounier-Kuhn syndrome, Chest radiographs, CT.

ÖZET

Trakeobronşiomegali (Mounier-Kuhn sendromu)

Trakeobronşiomegali (Mounier-Kuhn sendromu) belirgin kistik trakeobronşiyal dilatasyon olarak tanımlanır. Trakeobronşiomegali (TBM) öncelikle 40 ila 50 yaş arasındaki erkekleri etkileyen nadir görülen bir durumdur. TBM etyolojisi bilinmemektedir. Patolojik olarak trakea ve santral bronşların kas ve elastik elemanlarının atrofisi vardır. TBM ve solunum sisteminin ilgili patolojisinin tanısı esas olarak düz akciğer grafileri ve BT gibi radyolojik incelemelere dayanmaktadır. Tekrarlayan alt solunum yolu enfeksiyonları öyküsü olan TBM'li iki olgu sunulmuştur.

Anahtar Sözcükler: Trakeobronşiomegali, Mounier-Kuhn sendromu, Akciğer grafileri, BT.

In 1932, Mounier–Kuhn first presented the clinical, radiographic, and bronchoscopic findings of a syndrome which consisted of dilatation of the trachea and main-stem bronchi, and recurrent lower respiratory tract infections (1, 2). Various terms have been used to describe this uncommon disorder. In 1962, Katz et al. introduced tracheobronchomegaly (TBM) as a simple and appropriate designation of this condition (3). It is a rare condition primarily affecting men between the ages of 40 to 50 years (4). Reports of this disease in childhood are extremely rare (1, 5).

TBM is diagnosed in women from chest radiographs when the transverse and sagittal diameters of the trachea exceed 21 mm and 23 mm, respectively, and when the transverse diameters of the right and left main bronchi exceed 19.8 mm and 17.4 mm, respectively. In men it is diagnosed when the transverse and sagittal diameters of the trachea exceed 25 mm and 27 mm, respectively, and when the transverse diameters of the right and left main bronchi exceed 21.1 mm and 18.4 mm, respectively (4, 6).

TBM was also described in association with Ehlers-Danlos syndrome, Marfan syndrome, Kenny-Caffey syndrome, connective tissue diseases, ataxia-telangiectasia, Bruton-type agammaglobulinemia, ankylosing spondylitis, and cutis laxa (2, 7-12).

CASE REPORT

In this study we present two cases of tracheobronchomegaly.

Case 1

A 47 year-old male patient was admitted to our hospital with recurrent pneumonia, fever, dyspnea, purulent sputum production and cough complaints. He had a 3-year history of dyspnea and he was taking therapy for chronic obstructive pulmonary disease. Plain chest radiographs showed tracheal dilatation and bilateral increased opacities in both lower lobes (Figure 1).

Axial computed tomography (CT) of the chest revealed marked tracheobronchial dilatation with the diameters of the trachea being 42x31 mm, the right main

^aCorresponding Adress: Dr. Ayşe MURAT AYDIN, Firat University Faculty of Medicine, Department of Radiology, Elazığ, Turkey
e-mail: aysemurat@hotmail.com

Received/Geliş Tarihi: 19.11.2013

Accepted/Kabul Tarihi: 15.04.2014

bronchi 30 mm, and the left main bronchi 23 mm. There were consolidations in lower lobes of both right and left lungs that were consistent with pneumonia. Additionally, focal bronchiectasis and secretion retentions were present in the lower lobe of the left lung. Centrilobular emphysema was present in both lungs (Figure 2).

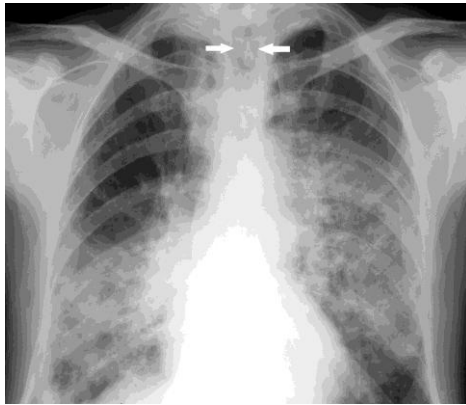


Figure 1. Plain chest radiograph of first case shows tracheal dilatation (arrows) and bilateral lower zone opacities which is more prominent on right (consolidation).

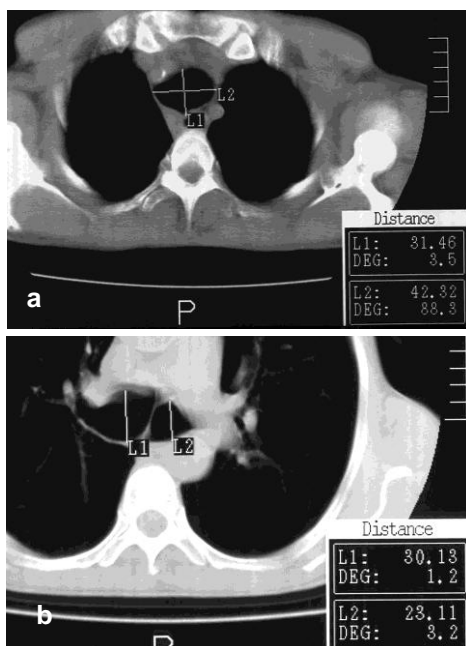


Figure 2. One year later, control axial chest CT of same case shows (a) increased diameters of trachea and (b) main bronchi.

Case 2

A 57-year-old male patient was admitted to our hospital with dyspnea and sputum production complaints which had been present for 2 years. Plain chest radiographs showed tracheal dilatation. An axial CT of the chest showed increased diameters of the trachea at 37x33 mm, the right main bronchi at 25 mm and the left main bronchi at 19 mm (Figure 3). A corrugated effect was seen in the right main bronchi

(Figure 4). There was minimal bronchiectasis in both lower lobes of the lungs.

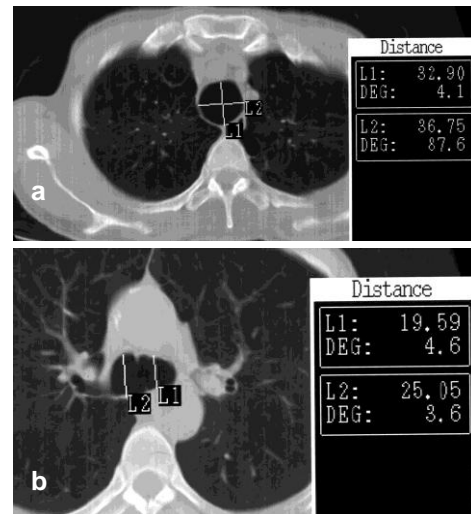


Figure 3. Second case's axial CT of the chest shows (a) increased diameters of trachea and (b) main bronchi.

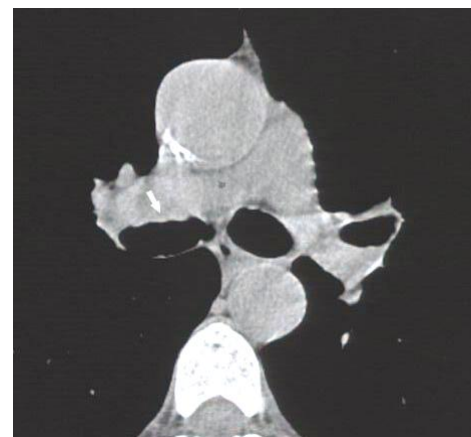


Figure 4. Second case's axial chest CT shows marked enlargement of main bronchi and corrugated appearance of bronchial wall (arrow).

Our cases refused histopathologic assesment, so we did not give any histopathologic result.

DISCUSSION

TBM is defined as marked cystic tracheobronchial dilatation. The etiology of TBM is unknown. Pathologically, there is atrophy of the muscular and elastic elements of the trachea and central bronchi (4, 11, 13, 14). Radiologic findings of an irregular air column reflect the “corrugated” effect that is produced when redundant mucosa prolapses through the tracheal rings (4, 11). Also, a CT revealed the presence of the corrugated effect in the right main bronchi in our second case. Because of the absence of normal cartilage, the trachea and bronchi can collapse during coughing or normal expiration. As a result of this ineffective cough mechanism, patients exhibit retention of secretions with resultant recurrent pneumonia, bronchiectasis, and fibrosis (4, 11, 13, 14). Our cases were complaining of

symptoms like cough, sputum production, fever and dyspnea that indicate lower respiratory disease.

TBM has 3 subtypes. In type 1, there is a slight symmetric dilation in the trachea and main bronchi. In type 2, the dilation and diverticula are distinct. In type 3, diverticular and saccular structures extend to the distal bronchi. The main problems associated with this disease are an ineffective cough consequent to pathologic dilation in the tracheobronchial tree and the impairment of mucociliary activity. These cause difficulty in expectorating secretions and lead to recurrent lower respiratory tract infections (14).

The clinical presentation varies widely, from minimal disease in which lung function is preserved to severe respiratory failure and death. Involvement occurs at different levels, from the trachea down to the 4th bronchial branch. Cases are often sporadic (14). At least 50% of cases are asymptomatic until after age 29 years (15). Since a considerable number of patients with TBM seem to be completely asymptomatic, TBM is probably underdiagnosed (1). Sometimes an aggressive form in a young child can result in death (5).

The discussion of whether TBM is an acquired or a congenital disorder goes back to the first postmortem description of this condition by Czyhlarz in 1897, who found atrophy of the longitudinal fibers and thinning of the muscularis of the central airways in TBM. Many authors favor a congenital basis of this disorder and argue that quantitative and qualitative abnormalities of elastic fibers, collagen bundles, and smooth muscle of the trachea and main bronchi, as demonstrated by histopathologic examinations, suggests an inborn weakness of the tracheobronchial wall structures. The hypothesis of TBM being a congenital disorder is further supported by its occasional association with other connective tissue disorders such as cutis laxa or Ehlers-Danlos syndrome. In contrast, other investigators believe that TBM is an acquired disorder, since most

cases were diagnosed no earlier than the fourth decade of life and are without evidence of an associated connective tissue disorder (1).

The normal range of the sagittal and coronal diameters of trachea in adults without any respiratory disease has been established, but there is no data about the dimensions of the main bronchi (5). Although Woodring et al. (6) have described the radiographic limits of both the trachea and main bronchi for both sexes, we could not find enough data to define accurate diameters for abnormal tracheal dilatation.

The diagnosis of TBM and the associated pathology of the respiratory system are primarily based on radiographic examinations such as plain chest radiographs and CT scans. Bronchoscopy may be helpful for confirmation of the diagnosis (1). Pulmonary function tests may reveal an obstructive pattern and increased residual volume (5, 11).

A prompt diagnosis may be particularly beneficial for children and adolescents, as it allows for initiation of early therapy (1). There is no curative treatment for TBM. Therapy is aimed at minimizing the damage caused by stasis of secretions. Postural drainage techniques and the early and vigorous treatment of intercurrent infections are the mainstays of supportive treatment (5). There is no role for surgery (11, 14). The use of tracheobronchial prostheses may improve symptoms in adults (5).

There are fewer than 100 case reports in the literature with only 2 reports of successful lung transplantation for patients with this syndrome. TBM is a rare disease with significant anesthetic and airway implications impacting the safety of the patients. In addition to difficulties with lung isolation, great care has to be taken to avoid damage to the tracheal walls due to extreme fragility and, therefore, a high risk for tracheal rupture (16).

REFERENCES

1. Benesch M, Eber E, Pflieger A, Zach MS. Recurrent lower respiratory tract infections in a 14-year-old boy with tracheobronchomegaly (Mounier-Kuhn syndrome). *Pediatr Pulmonol* 2000; 29: 476-9.
2. Krustins E, Kravale Z, Buls A. Mounier-Kuhn syndrome or congenital tracheobronchomegaly: A literature review. *Respir Med* 2013; 107: 1822-8.
3. Katz I, LeVine M, Herman P. Tracheobronchiomegaly. The Mounier-Kuhn syndrome. *Am J Roentgenol Radium Ther Nucl Med* 1962; 88: 1084-94.
4. Marom EM, Goodman PC, McAdams HP. Diffuse abnormalities of the trachea and main bronchi. *AJR Am J Roentgenol* 2001; 176: 713-7.
5. Hubbard M, Masters B, Chang AB. Rapidly progressing Case of Mounier-Kuhn syndrome in early childhood. *Pediatr Pulmonol* 2003; 36: 353-6.
6. Woodring JH, Howard RS 2nd, Rehm SR. Congenital tracheobronchomegaly (Mounier-Kuhn syndrome): a report of 10 cases and review of the literature. *J Thorac Imaging* 1991; 6: 1-10.
7. Hunter TB, Kuhns LR, Roloff MA, Holt JF. Tracheobronchomegaly in an 18 month old child. *AJR Am J Roentgenol* 1975; 123: 687-90.
8. Shivaram U, Shivaram I, Cash M. Acquired tracheobronchomegaly resulting in respiratory failure. *Chest* 1990; 98: 491-2.
9. Grünebaum M, Kornreich L, Horev G, Ziv N. Tracheobronchomegaly in Brachmann-de Lange Syndrome. *Pediatr Radiol* 1996; 26: 184-7.
10. Ayres JG, Pope FM, Reidy JF, Clarck TJH. Abnormalities of the lungs and thoracic cage in the Ehlers-Danlos syndrome. *Thorax* 1985; 40: 300-5.

11. Lazzarini-de-Oliveira LC, Costa de Barros Franco CA, Gomes de Salles CL, de Oliveira AC Jr. A 38-year-old man with tracheomegaly, tracheal diverticulosis, and bronchiectasis. *Chest* 2001; 120: 1018-20.
12. Noori F, Abduljawad S, Suffin DM, et al. Mounier-Kuhn syndrome: a case report. *Lung* 2010; 188: 353-4.
13. Gurney JW. The pathophysiology of airways disease. *J Thorac Imaging* 1995; 10: 227-35.
14. Celik B, Bilgin S, Yuksel C. Mounier-Kuhn syndrome: a rare cause of bronchial dilation. *Tex Heart Inst J* 2011; 38: 194-6.
15. Schwartz M, Rossoff L. Tracheobronchomegaly. *Chest* 1994; 106: 1589-90.
16. Subramani S, Freeman B, Rajagopal S. Anesthetic Considerations for Bilateral Lung Transplantation in Mounier-Kuhn Syndrome. *J Cardiothorac Vasc Anesth* 2014; 1053-0770: 605-8.